

EMPHYSEMATOUS CYSTITIS: A CASE REPORT

M Serajul Islam

Gordon Road, Barking, Essex, UK

ABSTRACT

We report a case of emphysematous cystitis, a 59 years old diabetic woman with history of vague abdominal pain, urinary frequency and high-grade fever. On clinical examination, she was markedly dehydrated, ill-looking obese lady with a temperature of 40.1°C and moderately tender over suprapubic area but Urinary bladder was not palpable. Urine dipstix was positive for blood and protein. CT scan of the abdomen revealed gas in and around the wall of urinary bladder.

Key Words: Emphysematous Cystitis, CT Scan.

INTRODUCTION

Emphysematous Cystitis is a rare disorder (about 200 cases reported in world literature). This condition was first reported in 1671.¹ It is most commonly seen in diabetic patients (about 50-60% of the cases).² Emphysematous cystitis has earned a good reputation as a benign condition in developed countries;¹ however mortality in developing countries is due to the delay before seeking medical advice³.

CASE REPORT

A 59 years old diabetic woman was admitted with 6 days history of vague abdominal pain, urinary frequency and spiking temperature up to 39.3 °C. She did not notice any pneumaturia or haematuria although urine dipstix was positive for blood and protein. She was taking Insulin (human mixtard 30) for her diabetes. She was treated by her G.P with trimethoprim 200mg BD for suspected UTI but she remained unwell and was referred to hospital. On clinical examination, she was markedly dehydrated, ill-looking obese lady with a temperature of 40.1 °C, BP 100/62 mm Hg, heart rate 106/min. She was moderately tender over suprapubic area but urinary bladder was not palpable, her bowel sounds were present and there were no signs of peritonism. Laboratory results showed WCC of 23x 10⁹/L, serum creatinine 177micro mol/L, urea 27 mmol/L, glucose 26mmol/L, CRP 246mg/L, blood culture was sterile but E. Coli was isolated from urine. Abdominal X-Ray did not show any pathology but CT scan of the abdomen revealed gas in urinary bladder. Fluid and electrolytes were corrected and i.v gentamicin and ceftriaxone were started subsequently gentamicin was stopped as organism was sensitive to ceftriaxone. Her diabetes was controlled with i.v. insulin sliding scale for 4 days,

subsequently human mixtard 30 was re-started. Her condition improved gradually and was discharged home after 10 days of i.v. antibiotic with a further 7 days supply of oral ciprofloxacin to which the E. Coli was sensitive too.

DISCUSSION

Emphysematous cystitis is most commonly observed in diabetic patients. It is characterised by gas in and around urinary bladder wall. Factors contributing to the development of this condition are poorly controlled DM, recurrent UTI, indwelling urinary bladder catheter, bladder outlet obstruction, neurogenic bladder and after kidney transplantation.^{4,5}

It should be differentiated from other

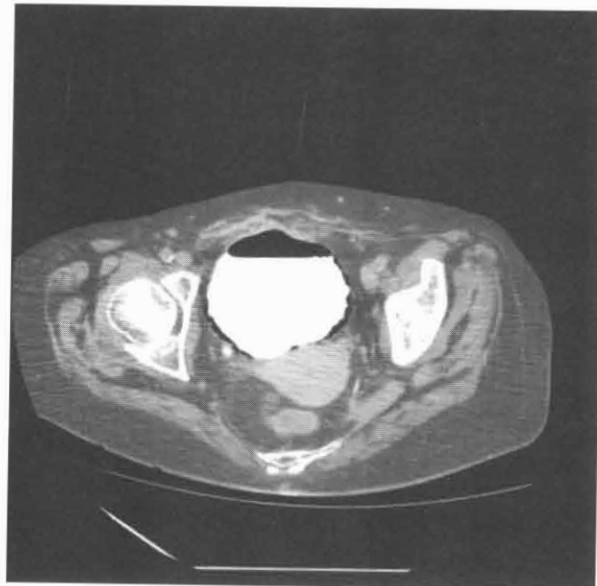


Fig1. CT scan of abdomen showing gas in urinary bladder wall (arrows)

causes of air in urinary bladder, e.g. air in bladder lumen after trauma or instrumentation, fistula between bladder and bowel/vagina. Pneumaturia is a common finding⁶ and other features are similar to UTI i.e lower abdominal pain, frequency, urgency, fever and haematuria. E.Coli is the most common organism; however, klebsiella, proteus, staph aureus, streptococci, enterobacter, candida albicans, nocardia, clostridium perfringens, bacteroides fragilis have also been implicated.^{6,7}

Diagnosis can be made incidentally on plain films but CT scan of abdomen most reliably demonstrate the location and extent of the gas collection.⁸ Diagnosis is often made late as the condition is rare and clinical features are non-specific. On the whole, the prognosis of this condition is favourable, but severe necrotising cystitis require cystectomy, and a mortality rate of 20%.⁶ Outcome depends on early diagnosis with correction of any predisposing factor, strict diabetic control, prolonged course of appropriate antibiotic, relief of urinary outlet obstruction and surgical debridement where necessary.

Acknowledgement: Dr Goff, Consultant radiologist (Raigmore Hospital), for giving access to CT Scan.

REFERENCES

1. Bailey H. Cystitis Emphysematosa: 19 cases with intra-luminal and interstitial collection of gas. *Am J Roentgenol* 1961; 86: 850-62.
2. O'Connor L A, De Guzman J. Emphysematous Cystitis: A radiographic diagnosis. *Am J Emer Med* 2001 ; 19: 211-213.
3. Chary K S, Rao M S, Malik N N, Vaidyanathan S S, Chandrasekar D D, Swamy R P, Dash R J. Emphysematous Infection of urinary tract (report of 3 cases). *J Postgrad Med* 1983;29:39-41.
4. Akalin E, Hyde C, Schmitt G, Kaufman J, Hamburger R J. Emphysematous cystitis and pyelitis in diabetic renal transplant recipient. *Transplantation* 1996; 62: 1024-6.
5. Kalra O P, Malik N, Minz M, Gupta K L, Sakhuja V, Chugh K S. Emphysematous pyelonephritis and cystitis in a renal transplant recipient-computed tomographic appearance. *Int J Artif Organs* 1993;16:41-4.
6. Quint H J, Drach G W, Rappaport W D, Hoffmann C J. Emphysematous cystitis-a review of spectrum of disease. *J Urol* 1992; 147: 134-137.
7. Wortmann G, Fleckenstein J. Incidental discovery of emphysematous cystitis. *South Med J* 1998; 91: 785-786.
8. Joseph R C, Amendola M A, Artze M E. Genitourinary tract gas-Imaging evaluation. *Radiographic* 1996; 16: 295-308.

Address for Correspondence:

Dr Md Serajul Islam
14 Gordon Road, Barking,
Essex, IG11 7XQ,UK
E-Mail: mdserajul_islam@yahoo.co.uk